

A Male Patient with Left Inguinal Bulge and Left Scrotal Pain

Suresh V. Phatak*, Megha Manoj, Soumya Jain, K. B. Harshith Gowda

Department of Radio-Diagnosis, Jawaharlal Nehru Medical College, Datta Meghe Institute of Medical Sciences, Wardha, Maharashtra, India

SECTION 1 – QUIZ

Case

A 57-year-old male presented with complaints of dull aching pain in the left scrotum and a bulge in the left inguinal region. There was no history of trauma or fever. Ultrasound examination of the inguinoscrotal region was performed [Figures 1-3].

Declaration of patient consent

The authors certify that they have obtained all appropriate patient consent forms. In the form the patient has given his consent for his images and other clinical information to be reported in the journal. The patient understands that his name and initials will not be published and due efforts will be made to conceal the identity, but anonymity cannot be guaranteed.

Financial support and sponsorship

Nil.

Conflicts of interest

There are no conflicts of interest.

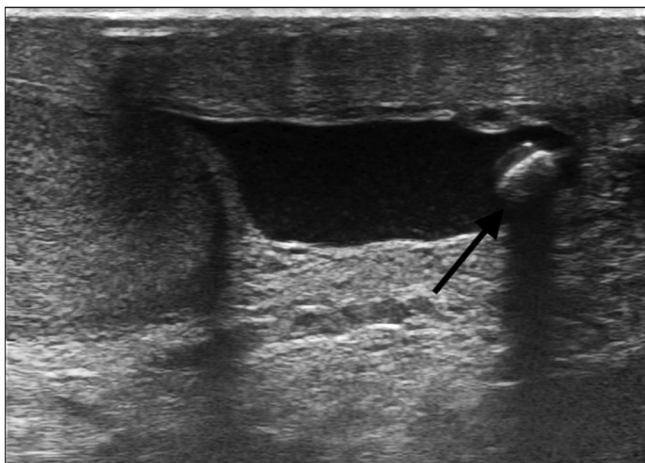


Figure 1: Greyscale ultrasound image of the left scrotal sac

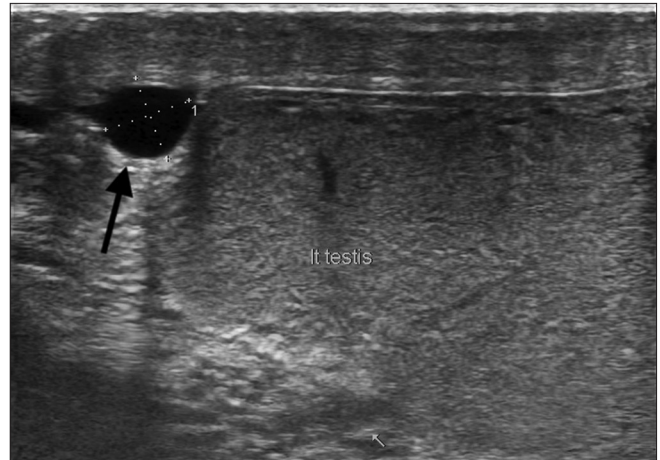


Figure 2: Greyscale Ultrasound image of upper pole of left testis

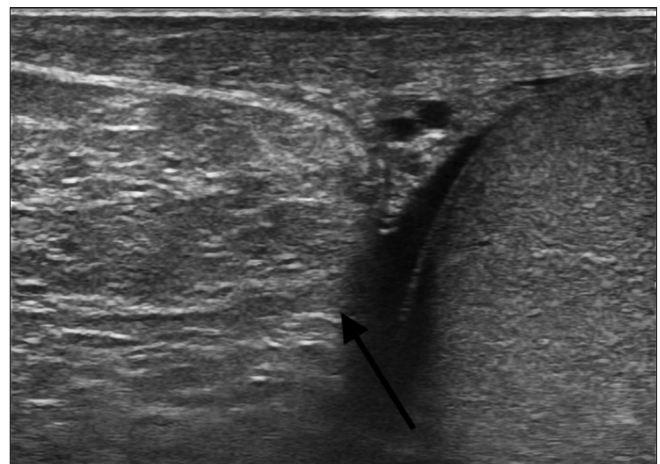


Figure 3: Greyscale Ultrasound image of left inguinoscrotal region

Address for correspondence: Dr. Suresh V. Phatak,
Department of Radio-Diagnosis, Jawaharlal Nehru Medical College,
Datta Meghe Institute of Medical Sciences, Sawangi, Wardha - 442 001,
Maharashtra, India.
E-mail: suresh_phatak@yahoo.com

Received: 14-12-2020 Revised: 23-02-2021 Accepted: 11-03-2021 Available Online: 02-07-2021

Access this article online

Quick Response Code:



Website:
www.jmuonline.org

DOI:
10.4103/JMU.JMU_170_20

This is an open access journal, and articles are distributed under the terms of the Creative Commons Attribution-NonCommercial-ShareAlike 4.0 License, which allows others to remix, tweak, and build upon the work non-commercially, as long as appropriate credit is given and the new creations are licensed under the identical terms.

For reprints contact: WKHLRPMedknow_reprints@wolterskluwer.com

How to cite this article: Phatak SV, Manoj M, Jain S, Gowda KB. A male patient with left inguinal bulge and left scrotal pain. J Med Ultrasound 2022;30:76.